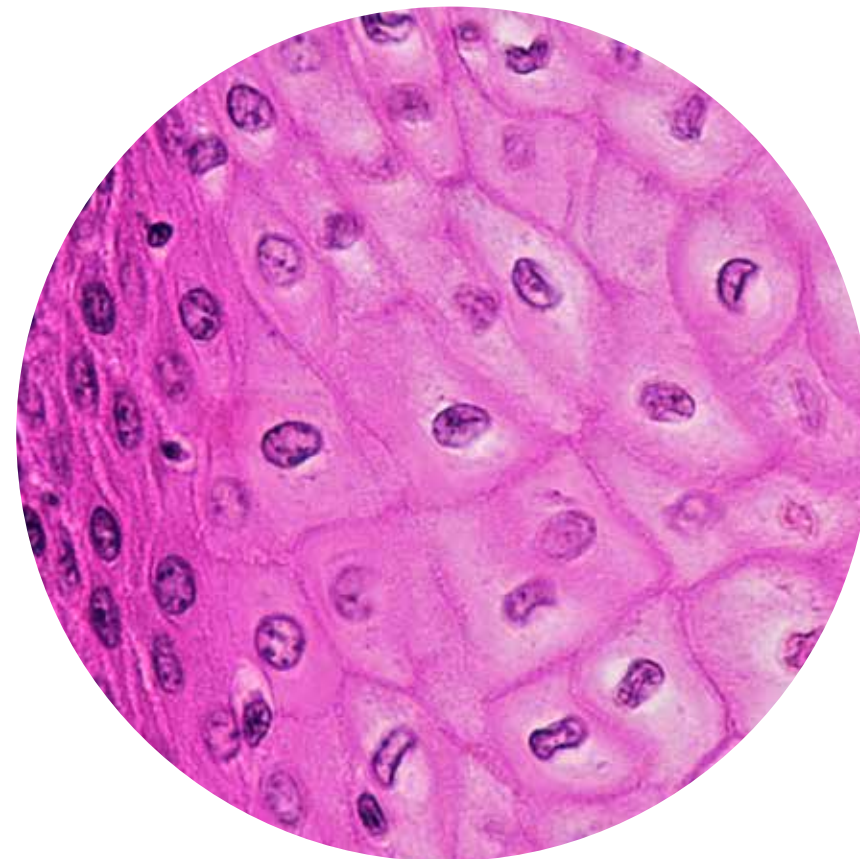


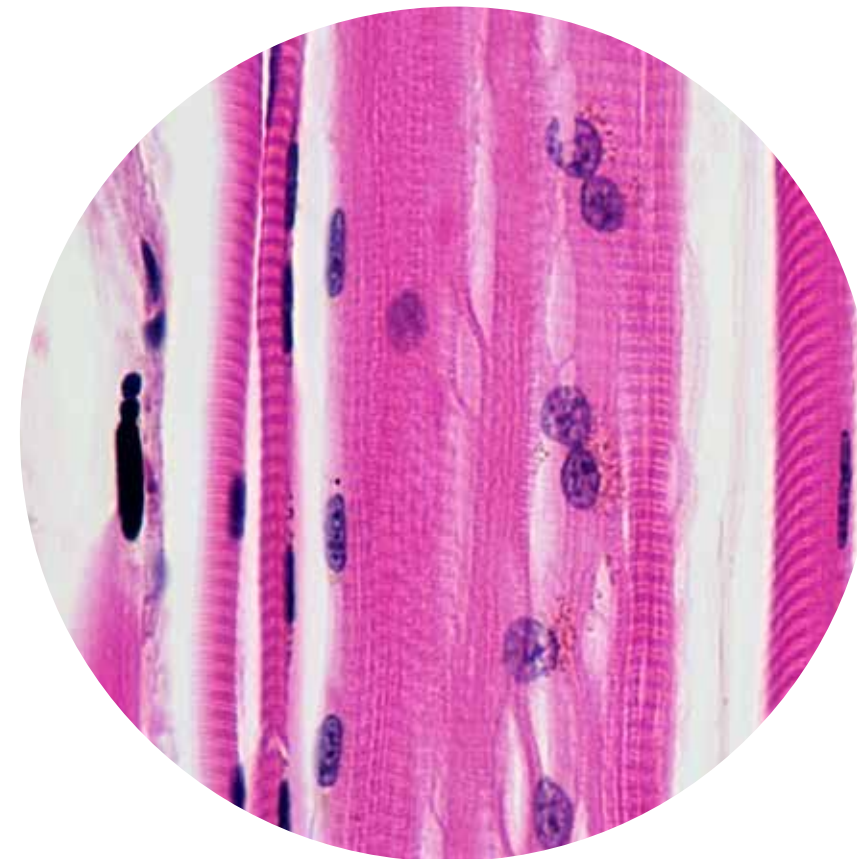
Zapamiętaj



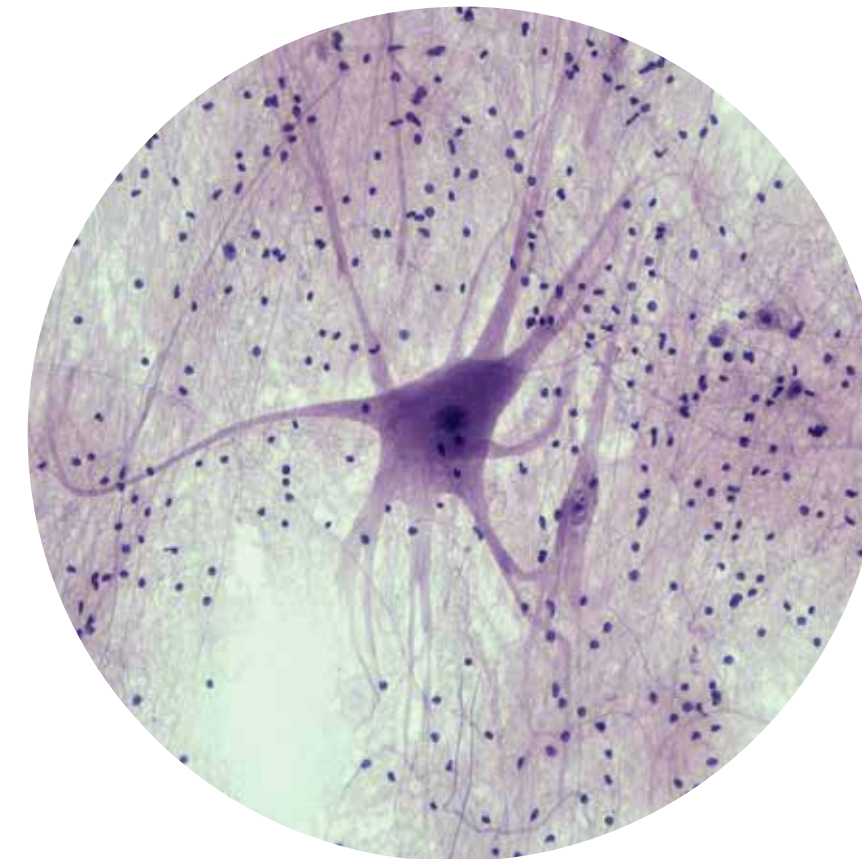podstawowe typy TKANEK ZWIERZĘCYCH



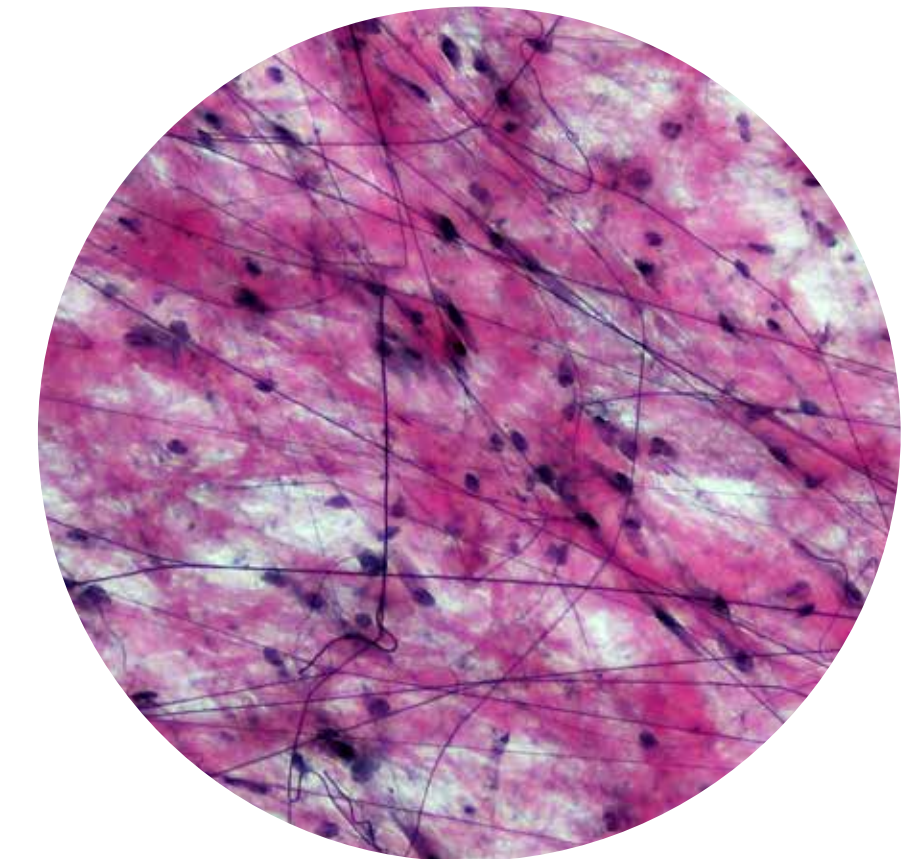
NABŁONKOWA



MIĘŚNIOWA



NERWOWA



ŁĄCZNA